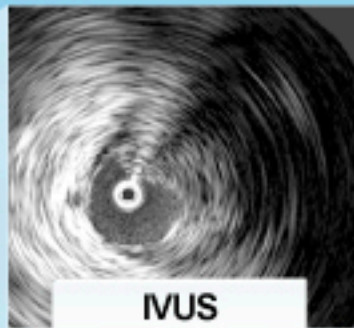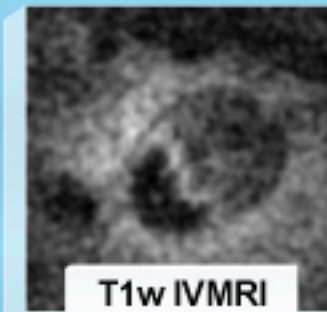
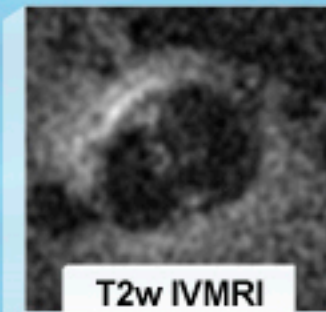


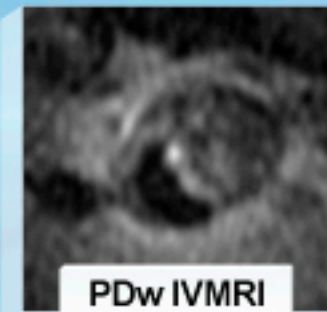IVUS



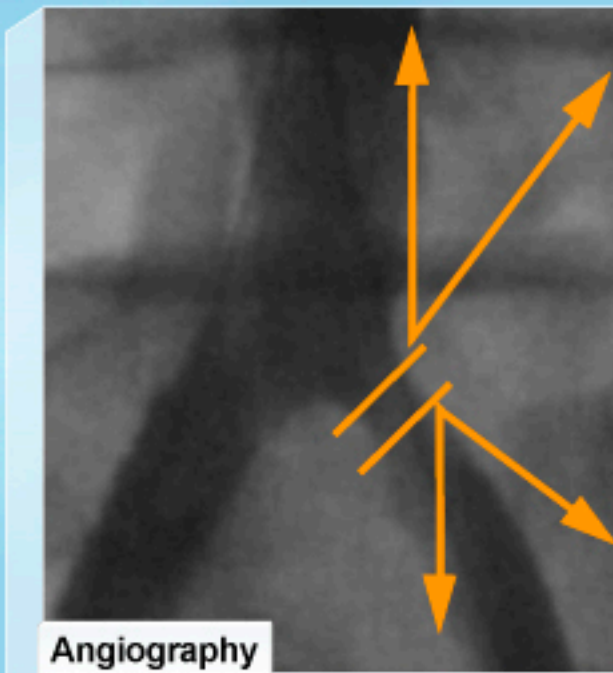
T1w IVMRI



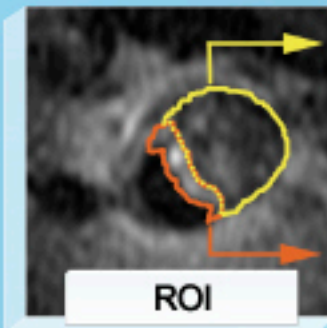
T2w IVMRI



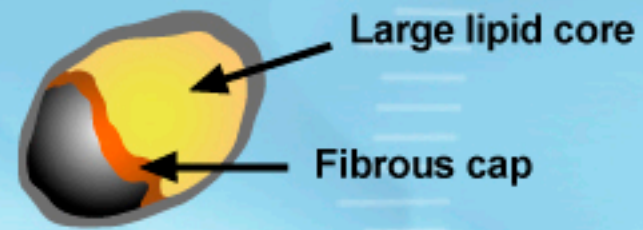
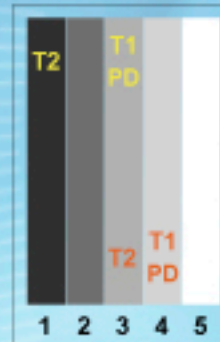
PDw IVMRI



Angiography

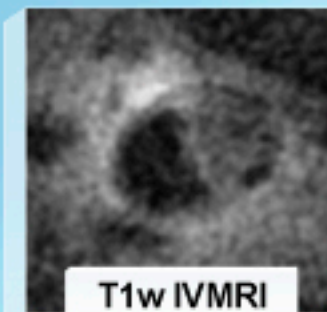


ROI

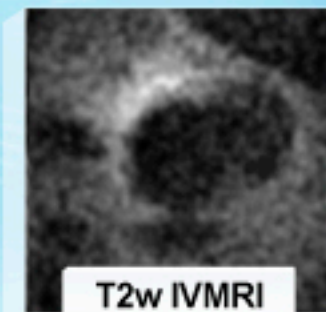


Large lipid core

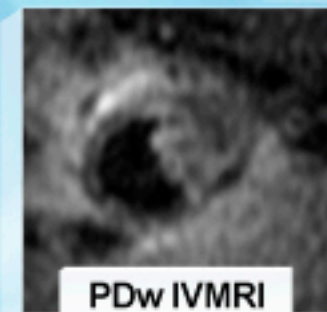
Fibrous cap



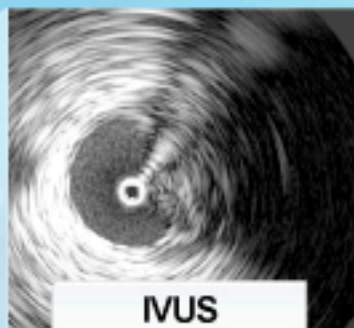T1w IVMRI



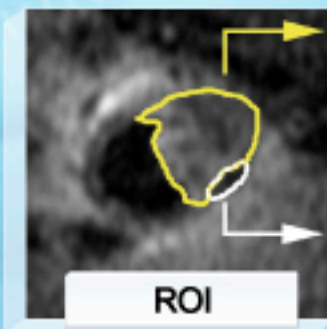
T2w IVMRI



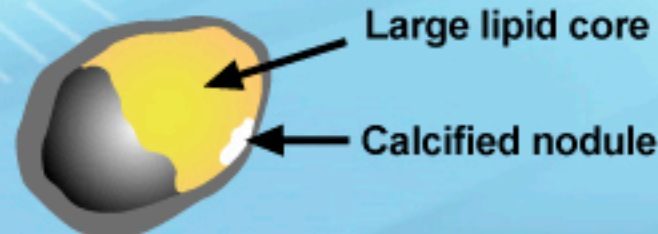

PDw IVMRI



IVUS



ROI



Large lipid core

Calcified nodule